Student's Journal of Health Research Africa
e-ISSN: 2709-9997, p-ISSN: 3006-1059
Vol.6 No. 9 (2025): September 2025 Issue
https://doi.org/10.51168/sjhrafrica.v6i9.2227
Review Article

Dual-energy CT quantitative parameters can improve the performance of differential diagnostics between Ameloblastomas and Odontogenic Keratocysts with solid components – A systematic review.

Dr. Karthik Shunmugavelu[1]*, Dr. Rajesh Gowtham[2]
[1]Bds, Mds Omfp, Msc London, Mfdsrcs England, Mfdsrcps Glasgow,
Faculty Affiliate Rcs Ireland, Affiliate Rcs Edinburgh, Mcip, Fibms
Usa, Masid Australia, Assistant Professor, Department of Dentistry
PSP Medical College Hospital and Research Institute, Tambaram, Kanchipuram main road
Oragadam Panruti Kanchipuram district Tamilnadu 631604 India
[2]MBBS MD (RD) Assistant Professor. Department of Radio Diagnosis, PSP Medical College and Hospital, Tambaram-Kanchipuram highway, Oragadam, Chennai 607106, Tamilnadu India

Abstract
Background
Technical constraints and a laborious workflow have likely led to underutilization of dual-energy CT. Clinical radiologists need a better understanding of the benefits of its benefits over single-energy CT. The fundamental idea of DECT involves acquiring data at two different X-ray energy levels to differentiate materials. Various acquisition techniques are available, including dual-tube systems, fast voltage switching, dual-layer detectors, split-filter techniques, and sequential scanning, each with its own pros and cons for clinical application. Up to 20% of cystic jaw lesions are OKCs, which are epithelial-lined cysts that are frequently linked to a nevoid basal cell carcinoma syndrome. Ameloblastomas (AMs) and odontogenic keratocysts (OKCs) are common, benign jaw lesions often discovered accidentally during routine radiographic examinations. Although benign, they can cause significant pain and tissue damage. Diagnosis typically involves clinical exams, radiography (such as panoramic X-rays, CT scans, or CBCT), and a subsequent biopsy. A key challenge is that AMs and OKCs look identical on conventional imaging, making primary differentiation by a radiologist difficult and highlighting a potential area where advanced techniques like DECT could offer improved diagnostic capabilities.
Material and Methods
Major databases such as Medline were explored through a detailed literature search, resulting in a systematic review pertaining to Dual-energy CT quantitative parameters that can improve the performance of differential diagnosis between ameloblastomas and odontogenic keratocysts with solid components.
Results
Ten original research scientific articles, dated between 2020 and 2024, about the mentioned topic were highlighted.
Conclusions
The ability to distinguish ameloblastomas from OKCs with solid components is much enhanced when DECT quantitative parameters are combined with traditional imaging features, providing a possible image-based diagnostic tool for clinical diagnosis. Detailed information regarding the DECT quantitative parameters can improve the performance of differential diagnosis between AMs and OKC, as discussed in this systematic review.

Key words: *Ameloblastomas; Dual-energy computed tomography; Odontogenic keratocysts, Jaw neoplasms, Iodine quantification, CT imaging techniques, Spectral CT.*
Submitted: *July 25, 2025* ***Accepted:*** *August 27, 2025* ***Published:*** *September 30, 2025*
Corresponding Author: *Dr. Karthik Shunmugavelu*
Email: ***drkarthiks1981@gmail.com***
Bds, Mds Omfp, Msc London, Mfdsrcs England, Mfdsrcps Glasgow, Faculty Affiliate Rcs Ireland, Affiliate Rcs Edinburgh, Mcip, Fibms Usa, Masid Australia. Assistant Professor, Department Of Dentistry, Psp Medical College Hospital and Research Institute, Tambaram, Kanchipuram main road, Oragadam, Panruti, Kanchipuram district, Tamilnadu 631604 India

Student's Journal of Health Research Africa
e-ISSN: 2709-9997, p-ISSN: 3006-1059
Vol.6 No. 9 (2025): September 2025 Issue
https://doi.org/10.51168/sjhrafrica.v6i9.2227
Review Article

INTRODUCTION:

Dual-energy CT, which scans an item at two distinct energies, allows for the identification of material properties that cannot be assessed with traditional single-energy CT imaging. Material decomposition based on variations in the material attenuation coefficients at various energies can be carried out using this imaging technique. There are two types of dual-energy analyses: those based on picture data and those based on raw data. Dual-energy analysis is more accurate when using raw data-based analysis since the beam-hardening impact is reduced. As the energy level drops on virtual monochromatic images, the iodine contrast rises, making contrast-enhanced lesions easier to see. Additionally, the use of material degradation techniques, such as iodine and edema pictures, improves the ability to identify lesions caused by illnesses that arise in routine clinical practice. Elements like iodine, calcium, or uric acid can be found and measured using DECT. Virtual non-contrasting images, iodine maps, virtual monochromatic images, mixed or weighted images, and material-specific images can all be produced using a variety of post-processing methods. Due to advancements in CT hardware and post-processing capabilities, dual energy CT has only been widely used in clinical practice during the last 20 years, despite the concept's initial introduction in 1970. DECT has many uses in emergency radiology, such as distinguishing between intracranial hemorrhage and contrast staining in stroke imaging, diagnosing pulmonary embolism, characterizing accidentally discovered renal and adrenal lesions, reducing beam and metal hardening artifacts, identifying uric acid renal stones, and diagnosing gout. In clinical practice, ameloblastomas and odontogenic keratocysts (OKCs) are frequently seen. Ameloblastoma is the most prevalent odontogenic tumor, while OKC is a frequent cyst of odontogenic origin. They can occur anywhere in the jaws, but the posterior mandible, which includes the ramus and molar area, is where they most frequently manifest. They frequently share comparable radiographic characteristics in OPG and other X-ray pictures. Because of the similarity in the location, radiographic features, and clinical signs, it can be challenging to distinguish between OKC and ameloblastoma. However, because cysts and tumors differ in their biological function and how they are treated, getting a precise diagnosis before beginning treatment is an essential first step. Dual-energy CT (DECT) differentiates ameloblastoma from OKC by measuring material composition. It detects higher iodine concentration in the vascularized ameloblastoma and higher water content in the cystic, keratin-filled OKC.

MATERIAL AND METHODS:

"Dual energy CT" AND "jaw" AND "pathology" were the words used in the MEDLINE database using an advanced search strategy targeting different article categories between 2020 and 2024. The result was 78 articles, out of which we selected 10 articles based on the inclusion criteria. Inclusion criteria were case studies and scientific literature published between 2020 and 2024. Exclusion criteria were of scientific literature irrelevant to the specific search. This systematic review was conducted to determine the importance of Dual-energy CT quantitative parameters in improving the performance of differential diagnosis between ameloblastomas and odontogenic keratocysts with solid components, following the guidelines of the PRISMA (Preferred Reporting Items for Systematic Reviews and Meta-Analyses). PubMed, Lilacs, Embase, Scopus, and Web of Science were the sources of electronic databases. The search strategy used Boolean operators (AND and OR): [ALL ("Dual energy CT") AND (Jaw OR pathology OR CT imaging OR differential OR diagnosis) AND (cystic lesions)]. The following data were collected: first author, year, country of study, type of study, and outcome. The quality of studies was assessed using the STROBE (Strengthening the Reporting of Observational Studies) checklist.

Figure 1 – PRISMA flowchart

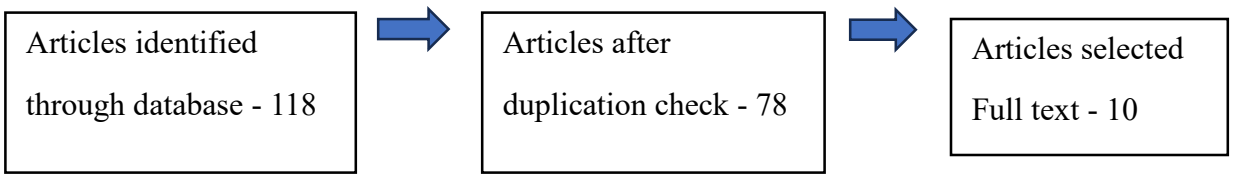

Student's Journal of Health Research Africa
e-ISSN: 2709-9997, p-ISSN: 3006-1059
Vol.6 No. 9 (2025): September 2025 Issue
https://doi.org/10.51168/sjhrafrica.v6i9.2227
Review Article

RESULTS

Ten articles were included in this systematic review based on the selection criteria. We analyzed and mentioned in the ten articles reviewed. This included only relevant research articles and excluded articles about nonspecific search terms.

Table 1 – An overview

Author	Title	Journal	Outcome
Deepak Justine Viswanathan, Ashu Seith Bhalla, Smita Manchanda 3, Ajoy Roychoudhury, Deepika Mishra, Asit Ranjan Mridha	Characterization of tumors of the jaw: Additive value of contrast enhancement and dual-energy computed tomography	Viswanathan DJ, Bhalla AS, Manchanda S, Roychoudhury A, Mishra D, Mridha AR. Characterization of tumors of the jaw: Additive value of contrast enhancement and dual-energy computed tomography. World Journal of Radiology. 2024 Apr 28;16(4):82. doi: 10.4329/wjr.v16.i4.82	Enhancement characteristics of solid components combined with dual-energy parameters offer a precise differentiation between jaw tumors
Padcha Tunlayadechanont, Thiparom Sananmuang	Dual-energy CT in head and neck applications	Tunlayadechanont P, Sananmuang T. Dual-energy CT in head and neck applications. The Neuroradiology Journal. 2025 Jan 8:19714009251313507. doi: 10.1177/19714009251313507	As DECT technology evolves, it enhances the efficacy of managing head and neck pathologies.
Makoto matsubara, osamu, Tanaka, Yasunori Muramatsu, Yasuhisa Hasegawa, masayuki Matsuo, Shinichiro Sumitomo	Usefulness of contrast-enhanced dual-energy computed tomography for detecting oral, head, and neck cancers	Matsubaram, Tanaka O, Muramatsu, Hasegawa Y, Matsuo M, Sumitomo S. Usefulness of contrast-enhanced dual-energy computed tomography for detecting oral, head, and neck cancers. Oral Surgery, Oral Medicine, Oral Pathology, and Oral Radiology. 2021 Jan 1;131(1):e34. DOI: 10.1016/j.oooo.2020.08.039	Visual estimation is superior with IDCT than with NRCT in terms of all aspects.
M Cellina, M Cè, E Grimaldi, G Mastellone, A Fortunati, G Oliva, C Martinenghi, G Carrafiello	The role of dual-energy computed tomography (DECT) in emergency radiology: a visual guide to advanced diagnostics	Cellina M, Cè M, Grimaldi E, Mastellone G, Fortunati A, Oliva G, Martinenghi C, Carrafiello G. The role of dual-energy computed tomography (DECT) in emergency radiology: a visual guide to advanced diagnostics. Clinical radiology. 83:106836. doi: 10.1016/j.crad.2025.106836.	DECT offers several advantages, enhanced visualisation, reduced exposure and contrast medium, and improved diagnostic accuracy
Jira Kitisubkanchana, Nor Hidayah Reduwan, Sopee Poomsawat, Suchaya Pornprasertsuk	Odontogenic keratocyst and ameloblastoma: radiographic evaluation	Kitisubkanchana J, Reduwan NH, Poomsawat S, Pornprasertsuk-Damrongsri S, Wongchuensoontorn C.	A unilocular radiolucent lesion with a smooth border, no root resorption, and causing

Student's Journal of Health Research Africa
e-ISSN: 2709-9997, p-ISSN: 3006-1059
Vol.6 No. 9 (2025): September 2025 Issue
https://doi.org/10.51168/sjhrafrica.v6i9.2227
Review Article

Damrongsri, Chanchai Wongchuensoontorn		Odontogenic keratocyst and ameloblastoma: radiographic evaluation. Oral radiology. 2021 Jan;37(1):55-65. doi: 10.1007/s11282-020-00425-2	mild or no bone expansion is suggestive of an OKC rather than an ameloblastoma
Naoki Kaneko Hu Chen, Junsei Sameshima, Taiki Sakamoto, Shintaro Kawano, Seiji Nakamura, Toru Chikui, Takeshi Mitsuyasu	Comparison of computed tomography findings between odontogenic keratocyst and ameloblastoma in the mandible: Criteria for differential diagnosis	Kaneko N, Sameshima J, Kawano S, Chikui T, Mitsuyasu T, Chen H, Sakamoto T, Nakamura S. Comparison of computed tomography findings between odontogenic keratocyst and ameloblastoma in the mandible: criteria for differential diagnosis. Journal of Oral and Maxillofacial Surgery, Medicine, and Pathology. 2023 Jan 1;35(1):15-22. doi.org/10.1016/j.ajoms.2022.07.016	CT findings are strikingly different between OKCs and ameloblastoma.
G C Fernández-Pérez, C Fraga Piñeiro, M Oñate Miranda, M Díez Blanco, J Mato Chaín, M A Collazos Martínez	Dual-energy CT: Technical considerations and clinical applications	Fernández-Pérez GC, Piñeiro CF, Miranda MO, Blanco MD, Chaín JM, Martínez MC. Dual-energy CT: Technical considerations and clinical applications. Radiologia. 2022;64(5):445-55. doi:10.1016/j.rxeng.2022.06.003.	Dual-energy CT also makes it possible to obtain virtual single-energy images.
Juergen Taxis, Natascha Platz Batista da Silva, Elisabeth Grau, Gerrit Spanier, Felix Nieberle, Michael Maurer, Steffen Spoerl, Johannes K Meier, Tobias Ettl, Torsten E Reichert, Nils Ludwig	Novel Three-Dimensional and Non-Invasive Diagnostic Approach for Distinction between Odontogenic Keratocysts and Ameloblastomas	Taxis J, da Silva NP, Grau E, Spanier G, Nieberle F, Maurer M, Spoerl S, Meier JK, Ettl T, Reichert TE, Ludwig N. Novel Three-Dimensional and Non-Invasive Diagnostic Approach for Distinction between Odontogenic Keratocysts and Ameloblastomas. Dentistry journal. 2023 Aug 11;11(8):193.	This represents a faster and non-invasive option for preoperative diagnosis.
Ahmad Abu-Omar, Nicolas Murray, Ismail T Ali, Faisal Khosa, Sarah Barrett, Adnan Sheikh, Savvas Nicolaou, Stefania Tamburrini, Francesca, Iacobellis, Giacomo Sica, Vincenza Granata, Luca Saba, Salvatore Masala, Mariano Scaglione	Utility of Dual-Energy Computed Tomography in Clinical Conundra	Abu-Omar A, Murray N, Ali IT, Khosa F, Barrett S, Sheikh A, Nicolaou S, Tamburrini S, Iacobellis F, Sica G, Granata V. Utility of Dual-Energy Computed Tomography in Clinical Conundra. Diagnostics (Basel, Switzerland). 2024 Apr 7;14(7):775. doi: 10.3390/diagnostics14070775	Advancing medical technology revolutionizes our ability to diagnose various disease processes.
Jo€ el Greffiera, Nicolas Villania, Didier Defeza,	Spectral CT imaging: Technical principles of	Greffier J, Villani N, Defez D, Dabli D, Si-Mohamed S. Spectral	Spectral computed tomography (CT)

Student's Journal of Health Research Africa
e-ISSN: 2709-9997, p-ISSN: 3006-1059
Vol.6 No. 9 (2025): September 2025 Issue
https://doi.org/10.51168/sjhrafrica.v6i9.2227
Review Article

Djamel Dablia, Salim Si-Mohamed	dual-energy CT and multi-energy photon-counting CT	CT imaging: technical principles of dual-energy CT and multi-energy photon-counting CT. Diagnostic and Interventional Imaging. 2023 Apr 1;104(4):167-77. Doi: 10.1016/j.diii.2022.11.003.	imaging encompasses a unique generation of CT systems based on a simple principle that makes use of the energy-dependent information present in CT images.

DISCUSSION

The head and neck are an anatomically complex region. Computed Tomography (CT) plays an important role in assessing the anatomical structures and translates to CT in differences in attenuation.1 Metallic devices in the oral cavity may cause important artifacts that may obscure the visualization of the normal anatomy and pathology.2 Some structures may be hyperdense, such as the thyroid gland, or may contain calcium, hindering the identification of enhancement after intravenous contrast administration.3

Dual-Energy CT (DECT) has many applications, providing additional information for radiologists.4 In diagnostic imaging, the photoelectric effect is the most important mechanism. This effect increases as the energy of the X-ray beam approaches the K edge of the atom; different atoms have different K edge values.5 In dual-energy CT, two different X-ray spectra are used to acquire two image datasets of the same anatomic region, allowing analysis of energy-dependent changes in the attenuation of different materials.6

Every material shows a relatively specific change in attenuation between images obtained with a high and a low-energy spectrum, and this allows better characterization of the tissues.7 Two different materials that show similar attenuation on images acquired with one of the two energy spectra may show substantial differences in their attenuation on the images acquired with the other spectrum and hence may be easily differentiated.8

There are multiple techniques available for dual energy CT imaging, which can be broadly classified as 9

- Dual source DECT
- Single source DECT – further divided based on the exact mechanism to generate two different energy spectra as:
- Fast kV switching
- Dual-layer detector
- Slow kV switching
- Dual spiral dual energy
- Twin beam dual energy

CT imaging, materials having different chemical compositions can be represented by the same, or very similar, CT numbers, making the differentiation and classification of different types of tissues extremely challenging.10 A classic example is the difficulty in differentiating between calcified plaques and iodine-containing blood.11 Although these materials differ in atomic number considerably, depending on the respective mass density or iodine concentration, the bone and iodinated blood may appear identical.12 The reason for these difficulties in differentiating and quantifying different tissue types is that the measured CT number of a voxel is related to the linear attenuation coefficient μ(E).13 It is not unique for any given material but is a function of the material composition, the photon energies interacting with the material, and the mass density of the material.14

Principles of DECT - DECT assesses attenuation by materials when submitted to high (140–150 kVp) and low energy (80–100 kVp) photon beams and acquires two datasets for the imaged anatomical range.15 Post-processing of dual-energy data can be conducted either before or in the projection-space domain or in the image-space domain, the reconstruction of high- or low-energy images, depending on the scanner.16

Postprocessing manipulation is utilized to reconstruct three different types of images: mixed images, material-specific images, and virtual monoenergetic images.17 Images derived from a combination of the high and low-energy datasets are created and are called mixed images. DECT material-specific images are created after evaluating the interaction of all body constituents with high and low energy levels.18

Postprocessing software is used to calculate the attenuation properties of each voxel at low and high energy, and a mathematical algorithm is used to determine the proportion of dominant materials. 19 Virtual non-contrast (VNC) images, sometimes referred to as virtual unenhanced (VUE) images depending on the vendor, are constructed after the voxels containing iodine are excluded from the image.20

Student's Journal of Health Research Africa
e-ISSN: 2709-9997, p-ISSN: 3006-1059
Vol.6 No. 9 (2025): September 2025 Issue
https://doi.org/10.51168/sjhrafrica.v6i9.2227
Review Article

These advantages are particularly evident in multiphasic studies such as CT angiography, CT urography, or multiphasic liver CT, where the necessity for a true non-contrast scan can be omitted. This can result in reductions in radiation dose ranging from 19% to 60%.21 It is also possible to superimpose a color-coded iodine overlay map (IOM) to quantify the amount of iodine in a specific region of interest.22

DECT allows the extrapolation of images for various single-energy levels. The resultant virtual monoenergetic image (VMI) simulates the image that would be obtained if the scanner were to emit a true monoenergetic beam of X-rays. 23 Using low-energy images improves the contrast-to-noise ratio by increasing the attenuation of materials with high atomic numbers, such as iodine, at the expense of decreased spatial resolution and increased noise.24

This facilitates the detection of iodine-containing structures such as contrast-opacified vessels and hypervascular tumors, rendering them more conspicuous.25 It also enables a decrease in the volume of intravenous iodinated contrast administered, which can be useful in patients with reduced renal function.26 Similarly, reductions of 50% in iodinated contrast dosage for CT urography and 40% for coronary CT angiography are also feasible.27

Conversely, high-energy images improve signal-to-noise ratio and ameliorate the effect of streak artifact, but with decreased attenuation of body constituents at higher energies.28 DECT postprocessing application also utilizes Rho-Z Maps (Z effective) to reconstruct images based on the material decomposition of substances.29 The Rho Z decomposition technique involves separation of materials based on their effective number (Rho) and electron density (z).30

Through material composition analysis, this application can identify and characterize different materials depending on their relative atomic number.31 Thus, dual energy CT can be defined as the use of attenuation values acquired with different energy spectra.32

Dual energy methods for CT were first investigated by Alvarez and Macovski in 1976. They demonstrated that even with polychromatic X-ray spectra, one can still separate the measured attenuation coefficients.33 Initial applications focused primarily on the characterization of lung, liver, and soft tissue composition. Clinical application of this technique focused primarily on bone densitometry measurements.34 In the 1980s, a modified commercial CT system (Siemens DR) used fast tube voltage switching to allow alternate projection measurements at the low and high tube potentials.35

Dual source CT is a CT system where two X-ray sources and two data acquisition systems are mounted on the same X-ray gantry, positioned orthogonally to one another on the gantry.36 Each x-ray source is equipped with an independent high-voltage generator, allowing independent control of both the x-ray tube potential and tube current.37 Thus, simultaneously acquired low- and high-energy images can be reconstructed with comparable image noise levels.38

DECT Systems - Dual-source scanner with dual detector arrays utilizes two X-ray sources and two data-acquisition systems mounted on the gantry in an orthogonal fashion.39

A high-energy dataset is obtained at 120 or 140 kVp, and a low-energy dataset is acquired at 80 or 100 kVp. Using two separate X-ray sources allows beam filtration and current modulation in each tube, resulting in optimization of image quality.40

Table 2: Strengths of Weaknesses of various DECT systems41

Technology	Advantages	Disadvantages
Dual source	Optimized image quality	Limited temporal and spatial resolution Small Field of View
Rapid kVp switching	Good temporal and spatial registration	Limited spectral separation, High noise-to-signal ratio of low-energy images, requires specialized hardware.
Dual-layer detectors	Excellent temporal and spatial resolution	High spectral overlap requires specialized hardware
Twin-beam filtration	Cost-effective Full spectral field of view available for image acquisition	Temporal discrepancy between high- and low-energy data, Cross-scatter, Intrinsic lower energies due to filtration, Overlapping spectra in the center and edge of the beam

Student's Journal of Health Research Africa
e-ISSN: 2709-9997, p-ISSN: 3006-1059
Vol.6 No. 9 (2025): September 2025 Issue
https://doi.org/10.51168/sjhrafrica.v6i9.2227
Review Article

Dual spin	Cost-effective, Optimized tube current modulation, Full spectral, Field of view No cross scatter	Spectral distortion secondary to motion artefact

Indications for the use of DECT include metal artifact related to implants, carotid atherosclerotic plaque assessment, head and neck tumor characterization, detection of parathyroid lesions, and delineation of paranasal sinus ventilation.42 Metal artifact reduction - Since high-energy X-ray photons penetrate deeper into the materials, beam-hardening and metallic streak artifacts are reduced.43 Simulated monochromatic images have been shown to decrease the amount of artifact caused by dental hardware in adjacent bone.44 This technique is particularly useful in maxillofacial imaging, in which braces and other metallic hardware are commonly encountered.45 A recent cadaveric study demonstrated that beam hardening artifacts from dental implants were subjectively decreased in most subjects by increasing the simulated monochromatic energy level of the reconstructed data.46

Material differentiation - As DECT can differentiate different materials from one another, calcium in the bones is readily separated from iodine in the contrast media.47 Hence, the bones in any angiography study can be easily removed. Similarly, calcified plaques can be removed for better visualisation of the lumen.48

Bone marrow edema is best visualised on MRI imaging. However, with DECT, it can differentiate calcium from other elements, and it can also selectively remove calcium from the region of interest. This is called the virtual non-calcium (VNC) technique 47

Material decomposition - The dual energy iodine maps allow us to evaluate lung perfusion; additionally, the dual energy iodine maps also improve visualisation of filling defects/thrombi in a small segmental or subsegmental artery.48 In patients with pulmonary thromboembolism, the dual energy perfusion maps show peripheral wedge-shaped areas of reduced perfusion representing perfusion defects.49

Atomic number maps (Rho/Z) – This allows calculation of the atomic number in the lesion, for the separation of various materials. Studies showed that non-enhancing renal cysts, including hyperattenuating cysts, can be discriminated from enhancing masses on effective atomic number maps 50

The morphological and quantitative spectral parameters obtained from DECT imaging were evaluated for the differentiation of various tumors of the jaw.51 The primary goal was to identify qualitative and quantitative parameters for distinguishing ameloblastomas from non-ameloblastomas. 52

On investigating the potential of using quantitative information provided by both the virtual monochromatic images and MD images in dual-energy spectral CT imaging for the differentiation of ameloblastomas and non-ameloblastomas.53 Iodine, as the main component of a contrast medium, allows the assessment of vascular beds and intercellular spaces, and it facilitates the differentiation of lesions at various locations in the body.54 DECT allows the quantitative assessment of the concentration of iodine accumulated in a unit of tissue volume. The degree of angiogenesis indicates the degree of viability, the degree of malignancy, and the vascularization sources.55 Multiple stromal factors, including growth and angiogenic factors, extracellular matrix components, and proteinases, are overexpressed and linked to the development of this tumor, where they play critical roles in invasion, growth, and progression with aggressive behavior.56 The non-ameloblastomas included a heterogeneous sample within the group that ranged from cystic lesions 57

This was in accordance with the earlier studies, which showed that central giant cell lesions had significantly higher angiogenetic potential compared to ameloblastomas.58 In a comparison of ameloblastomas with OKCs, like morphological features, all quantitative parameters showed significant differences between the two lesions.59

The water concentration of the cystic areas differs significantly between the ameloblastomas and OKCs, indicating that the density of the cystic components with suppressed iodine information varies between these odontogenic tumors.60 Cystic spaces in the ameloblastomas usually contain slightly proteinaceous fluids, occasionally associated with colloidal materials. The cyst lumen of OKCs often contains desquamated keratin.61

Therefore, it is that such desquamated keratin increased the viscosity of fluids in the lumen, thereby increasing the value of water concentration in the iodine images compared with ameloblastomas, in which increases in viscosity may be minimal.62 Ameloblastomas showed significantly increased values of DECT parameters, compared to non-

Student's Journal of Health Research Africa
e-ISSN: 2709-9997, p-ISSN: 3006-1059
Vol.6 No. 9 (2025): September 2025 Issue
https://doi.org/10.51168/sjhrafrica.v6i9.2227
Review Article

ameloblastomas, except for some cystic lesions like central giant cell granuloma 63

CONCLUSION

DECT can help differentiate among jaw cancers that closely resemble one another on conventional imaging, as well as aid in the anatomical and physiological classification of jaw tumors. By confirming the technical viability of single-source spectral CT imaging, which depends on the differentiation of iodine and water, as a useful tool for quantitatively differentiating ameloblastoma from other jaw tumors at roughly comparable dose equivalency of conventional CT, our study adds to the body of existing literature. One of the new methods in the field of medical picture analysis is radiomics. It was described as an imaging biomarker, derived from high-throughput extraction of features from medical images that are often invisible to the human eye. The features can be obtained using deep learning, also known as deep radiomics, or from mathematical formulas created by engineers. The DECT goes beyond the traditional SECT in terms of quantitative data. DECT offers several benefits for assessing the head and neck. In oncology, it aids tumor visualization, tissue characterisation, cancer staging by detecting thyroid cartilage invasion and lymph node metastases, treatment planning, and prognostication. For benign abnormalities, DECT also assists in the assessment of deep neck abscesses, identification of sialolithiasis, and characterization of parathyroid adenomas.

Acknowledgement

Declared none.

List of abbreviations

Short form Abbreviation
DECT Dual energy computer tomography
AMs Ameloblastoma
OKC Odontogenic keratocyst
CT computer tomography
CBCT Cone beam computer tomography
MRI Magnetic resonance imaging
Kv kilovolt
MD Material density

Source of funding

NIL

Conflict of interest

The authors declare no conflict of interest, financial or otherwise.

Authors' contribution

All authors have made substantial contributions to the conception and design of the study. All authors read and approved the final manuscript.

Author's biography:

RAJESH GOWTHAM,
M.D.

Tower 20 Door No 102, Skycity Apartments, Vanagaram, Chennai-95, Cell: +91-9677072102, Email: gowtham.rajesh@gmail.com

EXPERIENCE

Ultrasound Abdomen and Pelvis, KUB
Ultrasound Procedures: Fine Needle Aspirations, Catheterizations
X-rays: All plain films
X-ray Procedures: Intravenous Urethrography, Hysterosalpingography, Fistulogram, and Micturating
Cystourethrography, Barium meal, and swallow
Doppler: Fetal doppler, Arterial doppler, Venous doppler
CT: Brain, Thorax, Abdomen, Kidney, Ureter, Bladder, plain and contrast
CT Angiogram: Pulmonary Angiogram, Brain Angiogram, Upper and Lower Limbs
MR: Brain P&C, Spine, Knee, Elbow, Shoulder, Ankle
MR Procedures: Fistulogram and Magnetic Resonance Cholangiopancreatography
Fetal Medicine: Dating scan, Nuchal Translucency scan, Anomaly scan, Alpha-fetoprotein Index
Biophysical Profile.

EDUCATION

M.D- Saveetha University, Chennai (2016-2019)
M.B.B.S- S.R.M Medical College and Research Hospital (2010-2016)

Data availability

Data will be made available on request.

Student's Journal of Health Research Africa
e-ISSN: 2709-9997, p-ISSN: 3006-1059
Vol.6 No. 9 (2025): September 2025 Issue
https://doi.org/10.51168/sjhrafrica.v6i9.2227
Review Article

REFERENCES

1. Wippold FJ. Head and neck imaging: the role of CT and MRI. Journal of Magnetic Resonance Imaging: An Official Journal of the International Society for Magnetic Resonance in Medicine. 2007 Mar;25(3):453-65. doi: 10.1002/jmri.20838. https://doi.org/10.1002/jmri.20838
2. Gnannt R, Winklehner A, Goetti R, Schmidt B, Kollias S, Alkadhi H. Low kilovoltage CT of the neck with 70 kVp: comparison with a standard protocol. American journal of neuroradiology. 2012 Jun 1;33(6):1014-9. doi: 10.3174/ajnr.A2910. https://doi.org/10.3174/ajnr.A2910
3. Holmes III DR, Fletcher JG, Apel A, Huprich JE, Siddiki H, Hough DM, Schmidt B, Flohr TG, Robb R, McCollough C, Wittmer M. Evaluation of non-linear blending in dual-energy computed tomography. European journal of radiology. 2008 Dec 1;68(3):409-13. doi: 10.1016/j.ejrad.2008.09.017 https://doi.org/10.1016/j.ejrad.2008.09.017
4. Johnson TR. Dual-energy CT: general principles. American Journal of Roentgenology. 2012 Nov;199(5_supplement):S3-8. doi: 10.2214/AJR.12.9116. https://doi.org/10.2214/AJR.12.9116
5. Curry TS, Dowdey JE, Murray RC. Christensen's physics of diagnostic radiology. Lippincott Williams & Wilkins; 1990. (doi: not available)
6. Alvarez RE, Macovski A. Energy-selective reconstructions in X-ray computerised tomography. Physics in Medicine & Biology. 1976 Sep 1;21(5):733. doi: 10.1088/0031 9155/21/5/002 https://doi.org/10.1088/0031-9155/21/5/002
7. Morhard D, Fink C, Graser A, Reiser MF, Becker C, Johnson TR. Cervical and cranial computed tomographic angiography with automated bone removal: dual energy computed tomography versus standard computed tomography. Investigative radiology. 2009 May 1;44(5):293-7. doi: 10.1097/RLI.0b013e31819b6fba. https://doi.org/10.1097/RLI.0b013e31819b6fba
8. Kaza RK, Platt JF, Cohan RH, Caoili EM, Al-Hawary MM, Wasnik A. Dual-energy CT with single-and dual-source scanners: current applications in evaluating the genitourinary tract. Radiographics. 2012 Mar;32(2):353-69. doi: 10.1148/rg.322115065. https://doi.org/10.1148/rg.322115065
9. Sommer WH, Johnson TR, Becker CR, Arnoldi E, Kramer H, Reiser MF, Nikolaou K. The value of dual-energy bone removal in maximum intensity projections of lower extremity computed tomography angiography. Investigative radiology. 2009 May 1;44(5):285-92. doi: 10.1097/RLI.0b013e31819b70ba. https://doi.org/10.1097/RLI.0b013e31819b70ba
10. Macovski A, Alvarez RE, Chan JH, Stonestrom JP, Zatz LM. Energy-dependent reconstruction in X-ray computerized tomography. Computers in biology and medicine. 1976 Oct 1;6(4):325-36. doi: 10.1016/0010-4825(76)90069-x. https://doi.org/10.1016/0010-4825(76)90069-X
11. Kalender WA, Klotz E, Suess C. Vertebral bone mineral analysis: an integrated approach with CT. Radiology. 1987 Aug;164(2):419-23. doi: 10.1148/radiology 164.2.3602380. https://doi.org/10.1148/radiology.164.2.3602380
12. Flohr TG, McCollough CH, Bruder H, Petersilka M, Gruber K, Süß C, Grasruck M, Stierstorfer K, Krauss B, Raupach R, Primak AN. First performance evaluation of a dual-source CT (DSCT) system. European radiology. 2006 Feb;16(2):256-68. doi: 10.1007/s00330-005-2919-2. https://doi.org/10.1007/s00330-005-2919-2
13. Johnson TR, Nikolaou K, Wintersperger BJ, Leber AW, von Ziegler F, Rist C, Buhmann S, Knez A, Reiser MF, Becker CR. Dual-source CT cardiac imaging: initial experience. European radiology. 2006 Jul;16(7):1409-15. doi: 10.1007/s00330-006-0298-y https://doi.org/10.1007/s00330-006-0298-y
14. Johnson TR, Krauss B, Sedlmair M, Grasruck M, Bruder H, Morhard D, Fink C, Weckbach S, Lenhard M, Schmidt B, Flohr T. Material differentiation by dual energy CT: initial experience. European radiology. 2007 Jun;17(6):1510-7. doi: 10.1007/s00330-006-0517-6. https://doi.org/10.1007/s00330-006-0517-6
15. Tatsugami F, Higaki T, Nakamura Y, Honda Y, Awai K. Dual-energy CT: minimal essentials for radiologists. Japanese journal of radiology. 2022

Student's Journal of Health Research Africa
e-ISSN: 2709-9997, p-ISSN: 3006-1059
Vol.6 No. 9 (2025): September 2025 Issue
https://doi.org/10.51168/sjhrafrica.v6i9.2227
Review Article

Jun;40(6):547-59. doi: 10.1007/s11604-021-01233-2. https://doi.org/10.1007/s11604-021-01233-2

16. Toia GV, Mileto A, Wang CL, Sahani DV. Quantitative dual-energy CT techniques in the abdomen. Abdominal Radiology. 2022 Sep;47(9):3003-18. doi: 10.1007/s00261-021-03266-7 https://doi.org/10.1007/s00261-021-03266-7
17. Murray N, Darras KE, Walstra FE, Mohammed MF, McLaughlin PD, Nicolaou S. Dual-energy CT in evaluation of the acute abdomen. Radiographics. 2019 Jan;39(1):264-86. doi: 10.1148/rg.2019180087. https://doi.org/10.1148/rg.2019180087
18. Graser A, Johnson TR, Hecht EM, Becker CR, Leidecker C, Staehler M, Stief CG, Hildebrandt H, Godoy MC, Finn ME, Stepansky F. Dual-energy CT in patients suspected of having renal masses: can virtual nonenhanced images replace true nonenhanced images?. Radiology. 2009 Aug;252(2):433-40. doi: 10.1148/radiol.2522080557 https://doi.org/10.1148/radiol.2522080557
19. Vlahos I, Godoy MC, Naidich DP. Dual-energy computed tomography imaging of the aorta. Journal of Thoracic Imaging. 2010 Nov 1;25(4):289-300. doi: 10.1097/RTI.0b013e3181dc2b4c. https://doi.org/10.1097/RTI.0b013e3181dc2b4c
20. Rajiah P, Parakh A, Kay F, Baruah D, Kambadakone AR, Leng S. Update on multienergy CT: physics, principles, and applications. Radiographics. 2020 Sep;40(5):1284-308. doi: 10.1148/rg.2020200038. https://doi.org/10.1148/rg.2020200038
21. Baliyan V, Shaqdan K, Hedgire S, Ghoshhajra B. Vascular computed tomography angiography technique and indications. Cardiovascular diagnosis and therapy. 2019 Aug;9(Suppl 1):S14. doi: 10.21037/cdt 2019.07.04 https://doi.org/10.21037/cdt
22. Sun H, Hou XY, Xue HD, Li XG, Jin ZY, Qian JM, Yu JC, Zhu HD. Dual-source dual-energy CT angiography with virtual non-enhanced images and iodine map for active gastrointestinal bleeding: image quality, radiation dose, and diagnostic performance. European journal of radiology. 2015 May 1;84(5):884-91. doi: 10.1016/j.ejrad.2015.01.013 https://doi.org/10.1016/j.ejrad.2015.01.013
23. Stolzmann P, Frauenfelder T, Pfammatter T, Peter N, Scheffel H, Lachat M, Schmidt B, Marincek B, Alkadhi H, Schertler T. Endoleaks after endovascular abdominal aortic aneurysm repair: detection with dual-energy dual-source CT. Radiology. 2008 Nov;249(2):682-91. doi: 10.1148/radiol.2483080193. https://doi.org/10.1148/radiol.2483080193
24. Chandarana H, Godoy MC, Vlahos I, Graser A, Babb J, Leidecker C, Macari M. Abdominal aorta: evaluation with dual-source dual-energy multidetector CT after endovascular repair of aneurysms-initial observations. Radiology. 2008 Nov;249(2):692-700. doi: 10.1148/radiol.2492080359. https://doi.org/10.1148/radiol.2492080359
25. Chung R, Dane B, Yeh BM, Morgan DE, Sahani DV, Kambadakone A. Dual-energy computed tomography: Technological considerations. Radiologic Clinics. 2023 Nov 1;61(6):945-61. doi: 10.1016/j.rcl.2023.05.002 https://doi.org/10.1016/j.rcl.2023.05.002
26. Shuman WP, Mileto A, Busey JM, Desai N, Koprowicz KM. Dual-energy CT urography with 50% reduced iodine dose versus single-energy CT urography with standard iodine dose. American Journal of Roentgenology. 2019 Jan;212(1):117-23. doi: 10.2214/AJR.18.19720. https://doi.org/10.2214/AJR.18.19720
27. Rotzinger DC, Si-Mohamed SA, Yerly J, Boccalini S, Becce F, Boussel L, Meuli RA, Qanadli SD, Douek PC. Reduced-iodine-dose dual-energy coronary CT angiography: qualitative and quantitative comparison between virtual monochromatic and polychromatic CT images. European radiology. 2021 Sep;31(9):7132-42. doi: 10.1007/s00330-021-07809-w. https://doi.org/10.1007/s00330-021-07809-w
28. Li B, Pomerleau M, Gupta A, Soto JA, Anderson SW. Accuracy of dual-energy CT virtual unenhanced and material-specific images: a phantom study. American Journal of Roentgenology. 2020 Nov;215(5):1146-54. doi: 10.2214/AJR.19.22372. https://doi.org/10.2214/AJR.19.22372

Student's Journal of Health Research Africa
e-ISSN: 2709-9997, p-ISSN: 3006-1059
Vol.6 No. 9 (2025): September 2025 Issue
https://doi.org/10.51168/sjhrafrica.v6i9.2227
Review Article

29. Abu-Omar A, Murray N, Ali IT, Khosa F, Barrett S, Sheikh A, Nicolaou S, O'Neill SB. The role of dual-energy CT in solid organ injury. Canadian Association of Radiologists Journal. 2024 May;75(2):417-27. doi: 10.1177/08465371231215669. https://doi.org/10.1177/08465371231215669
30. McCollough CH, Boedeker K, Cody D, Duan X, Flohr T, Halliburton SS, Hsieh J, Layman RR, Pelc NJ. Principles and applications of multienergy CT: Report of AAPM Task Group 291. Medical physics. 2020 Jul;47(7):e881-912. Doi: 10.1002/mp 14157. https://doi.org/10.1002/mp.14157
31. Lee SM, Kim SH, Ahn SJ, Kang HJ, Kang JH, Han JK. Virtual monoenergetic dual-layer, dual-energy CT enterography: optimization of keV settings and its added value for Crohn's disease. European radiology. 2018 Jun;28(6):2525-34. doi: 10.1007/s00330-017-5215-z. https://doi.org/10.1007/s00330-017-5215-z
32. Kalender WA, Klotz E, Kostaridou L. An algorithm for noise suppression in dual energy CT material density images. IEEE transactions on medical imaging. 1988 Sep 30;7(3):218-24. doi: 10.1109/42.7785. https://doi.org/10.1109/42.7785
33. Primak AN, Fletcher JG, Vrtiska TJ, Dzyubak OP, Lieske JC, Jackson ME, Williams Jr JC, McCollough CH. Noninvasive differentiation of uric acid versus non-uric acid kidney stones using dual-energy CT. Academic radiology. 2007 Dec 1;14(12):1441-7. doi: 10.1016/j.acra.2007.09.016. https://doi.org/10.1016/j.acra.2007.09.016
34. Goo HW, Goo JM. Dual-energy CT: new horizon in medical imaging. Korean journal of radiology. 2017;18(4):555-69. doi: 10.3348/kjr 2017.18.4.555. https://doi.org/10.3348/kjr.2017.18.4.555
35. Faby S, Kuchenbecker S, Sawall S, Simons D, Schlemmer HP, Lell M, Kachelrieß M. Performance of today's dual energy CT and future multi-energy CT in virtual non-contrast imaging and in iodine quantification: a simulation study. Medical physics. 2015 Jul;42(7):4349-66. Doi: 10.1118/1.4922654. https://doi.org/10.1118/1.4922654
36. Lee S, Choi YN, Kim HJ. Quantitative material decomposition using spectral computed tomography with an energy-resolved photon-counting detector. Physics in Medicine & Biology. 2014 Aug 28;59(18):5457. doi: 10.1088/0031-9155/59/18/5457. https://doi.org/10.1088/0031-9155/59/18/5457
37. Krauss B, Grant KL, Schmidt BT, Flohr TG. The importance of spectral separation: an assessment of dual-energy spectral separation for quantitative ability and dose efficiency. Investigative radiology. 2015 Feb 1;50(2):114-8. doi: 10.1097/RLI.0000000000000109. https://doi.org/10.1097/RLI.0000000000000109
38. Atak H, Shikhaliev PM. Dual energy CT with photon counting and dual source systems: comparative evaluation. Physics in Medicine & Biology. 2015 Nov 5;60(23):8949. doi: 10.1088/0031 9155/60/23/8949 https://doi.org/10.1088/0031-9155/60/23/8949
39. Forghani R, De Man B, Gupta R. Dual-energy computed tomography: physical principles, approaches to scanning, usage, and implementation: part 1. Neuroimaging Clinics of North America. 2017 Aug 1;27(3):371-84. doi: 10.1016/j.nic.2017.03.002. https://doi.org/10.1016/j.nic.2017.03.00
40. So A, Nicolaou S. Spectral computed tomography: fundamental principles and recent developments. Korean journal of radiology. 2020 Sep 10;22(1):86. doi: 10.3348/kjr 2020.0144 https://doi.org/10.3348/kjr.2020.0144
41. Fulwadhva UP, Wortman JR, Sodickson AD. Use of dual-energy CT and iodine maps in evaluation of bowel disease. Radiographics. 2016 Mar;36(2):393-406. doi: 10.1148/rg.2016150151. https://doi.org/10.1148/rg.2016150151
42. Coursey CA, Nelson RC, Boll DT, Paulson EK, Ho LM, Neville AM, Marin D, Gupta RT, Schindera ST. Dual-energy multidetector CT: how does it work, what can it tell us, and when can we use it in abdominopelvic imaging?. Radiographics. 2010 Jul;30(4):1037-55. doi: 10.1148/rg.304095175. https://doi.org/10.1148/rg.304095175
43. Ginat DT, Gupta R. Advances in computed tomography imaging technology. Annual review of biomedical engineering. 2014 Jul 11;16(1):431-53. Doi: 10.1146/annurev-bioeng-121813-113601. https://doi.org/10.1146/annurev-bioeng-121813-113601

Student's Journal of Health Research Africa
e-ISSN: 2709-9997, p-ISSN: 3006-1059
Vol.6 No. 9 (2025): September 2025 Issue
https://doi.org/10.51168/sjhrafrica.v6i9.2227
Review Article

44. Ghasemi Shayan R, Oladghaffari M, Sajjadian F, Fazel Ghaziyani M. Image quality and dose comparison of single-energy CT (SECT) and dual-energy CT (DECT). Radiology research and practice. 2020;2020(1):1403957. doi: 10.1155/2020/1403957 https://doi.org/10.1155/2020/1403957
45. Tanaka R, Hayashi T, Ike M, Noto Y, Goto TK. Reduction of dark-band-like metal artifacts caused by dental implant bodies using hypothetical monoenergetic imaging after dual-energy computed tomography. Oral surgery, oral medicine, oral pathology, and oral radiology. 2013 Jun 1;115(6):833-8. doi: 10.1016/j.oooo.2013.03.014. https://doi.org/10.1016/j.oooo.2013.03.014
46. Stolzmann P, Winklhofer S, Schwendener N, Alkadhi H, Thali MJ, Ruder TD. Monoenergetic computed tomography reconstructions reduce beam hardening artifacts from dental restorations. Forensic science, medicine, and pathology. 2013 Sep;9(3):327-32. doi: 10.1007/s12024-013-9420-z. https://doi.org/10.1007/s12024-013-9420-z
47. Ai S, Qu M, Glazebrook KN, Liu Y, Rhee PC, Leng S, McCollough CH. Use of dual-energy CT and virtual non-calcium techniques to evaluate post-traumatic bone bruises in knees in the subacute setting. Skeletal radiology. 2014 Sep;43(9):1289-95. doi: 10.1007/s00256-014-1913-7. https://doi.org/10.1007/s00256-014-1913-7
48. Guggenberger R, Gnannt R, Hodler J, Krauss B, Wanner GA, Csuka E, Payne B, Frauenfelder T, Andreisek G, Alkadhi H. Diagnostic performance of dual-energy CT for the detection of traumatic bone marrow lesions in the ankle: comparison with MR imaging. Radiology. 2012 Jul;264(1):164-73. doi: 10.1148/radiol.12112217. https://doi.org/10.1148/radiol.12112217
49. Pache G, Krauss B, Strohm P, Saueressig U, Blanke P, Bulla S, Schäfer O, Helwig P, Kotter E, Langer M, Baumann T. Dual-energy CT virtual noncalcium technique: detecting posttraumatic bone marrow lesions-feasibility study. Radiology. 2010 Aug;256(2):617-24. doi: 10.1148/radiol.10091230. https://doi.org/10.1148/radiol.10091230
50. Fink C, Johnson TR, Michaely HJ, Morhard D, Becker C, Reiser M, Nikolaou K. Dual-energy CT angiography of the lung in patients with suspected pulmonary embolism: initial results. In RöFo-Fortschritte auf dem Gebiet der Röntgenstrahlen und der bildgebenden Verfahren 2008 Oct (Vol. 180, No. 10, pp. 879-883). © Georg Thieme Verlag KG Stuttgart· New York. doi: 10.1055/s-2008-1027724. https://doi.org/10.1055/s-2008-1027724
51. Soluk-Tekkeşin M, Wright JM. The World Health Organization classification of odontogenic lesions: a summary of the changes of the 2017 (4th) edition. Turk Patoloji Derg. 2018 Jan 1;34(1):1-8. doi: 10.5146/tjpath 2017.01410.
52. Dunfee BL, Sakai O, Pistey R, Gohel A. Radiologic and pathologic characteristics of benign and malignant lesions of the mandible. Radiographics. 2006 Nov;26(6):1751-68. doi: 10.1148/rg.266055189. https://doi.org/10.1148/rg.266055189
53. McCollough CH, Leng S, Yu L, Fletcher JG. Dual- and multi-energy CT: principles, technical approaches, and clinical applications. Radiology. 2015 Sep;276(3):637-53. doi: 10.1148/radiol.2015142631 https://doi.org/10.1148/radiol.2015142631
54. Roele ED, Timmer VC, Vaassen LA, van Kroonenburgh AM, Postma AA. Dual-energy CT in head and neck imaging. Current radiology reports. 2017 Mar 29;5(5):19. doi: 10.1007/s40134-017-0213-0 https://doi.org/10.1007/s40134-017-0213-0
55. Odedra D, Narayanasamy S, Sabongui S, Priya S, Krishna S, Sheikh A. Dual energy CT physics primer for the emergency radiologist. Frontiers in radiology. 2022 Feb 24;2:820430. doi: 10.3389/fradi.2022.820430 https://doi.org/10.3389/fradi.2022.820430
56. Tawfik AM, Razek AA, Kerl JM, Nour-Eldin NE, Bauer R, Vogl TJ. Comparison of dual-energy CT-derived iodine content and iodine overlay of normal, inflammatory, and metastatic squamous cell carcinoma cervical lymph nodes. European radiology. 2014 Mar;24(3):574-80. doi: 10.1007/s00330-013-3035-3 https://doi.org/10.1007/s00330-013-3035-3
57. Li L, Zhao Y, Luo D, Yang L, Hu L, Zhao X, Wang Y, Liu W. Diagnostic value of single-source dual-

Student's Journal of Health Research Africa
e-ISSN: 2709-9997, p-ISSN: 3006-1059
Vol.6 No. 9 (2025): September 2025 Issue
https://doi.org/10.51168/sjhrafrica.v6i9.2227
Review Article

energy spectral computed tomography in differentiating parotid gland tumors: initial results. Quantitative Imaging in Medicine and Surgery. 2018 Jul;8(6):588. Doi: 10.21037/qims. 2018.07.07 https://doi.org/10.21037/qims

58. Ali K, Khan SZ, Sultana N, Alghamdi O, Mohammad S, Mokeem SA, Ali S, Abduljabbar T, Vohra F. Assessment of tumor angiogenesis by expression of CD 105 in ameloblastoma, odontogenic keratocyst and central giant cell lesion. Asian Pacific Journal of Cancer Prevention: APJCP. 2020 Nov;21(11):3373. doi: 10.31557/apjcp.2020.21.11.3373 https://doi.org/10.31557/APJCP.2020.21.11.3373
59. Hayashi K, Tozaki M, Sugisaki M, Yoshida N, Fukuda K, Tanabe H. Dynamic multislice helical CT of ameloblastoma and odontogenic keratocyst: correlation between contrast enhancement and angiogenesis. Journal of Computer-Assisted Tomography. 2002 Nov 1;26(6):922-6. doi: 10.1097/00004728-200211000-00011. https://doi.org/10.1097/00004728-200211000-00011
60. Ghosh A, Lakshmanan M, Manchanda S, Bhalla AS, Kumar P, Bhutia O, Mridha AR. Contrast-enhanced multidetector computed tomography features and histogram analysis can differentiate ameloblastomas from central giant cell granulomas. World Journal of Radiology. 2022 Sep 28;14(9):329. doi: 10.4329/wjr.v14.i9.329 https://doi.org/10.4329/wjr.v14.i9.329
61. Kotrashetti SM, John S, Kotrashetti V, Mishra R, Panday S, Kotrashetti S, Kotrashetti V, Mishra S. From Innocuous to Aggressive: A Case of Odontogenic Keratocyst Transforming to Unicystic Ameloblastoma. Cureus. 2025 Feb 10;17(2). doi: 10.7759/cureus 78806. https://doi.org/10.7759/cureus.78806
62. Cunha G, Rocha AF, Gabrielli MF, Gabrielli MA. Unicystic Ameloblastoma and Odontogenic Keratocyst: Difficulty in Differential Diagnosis. Oral Maxillofac Pathol J. 2021 Jan 1;12(1):38-40. (doi: not available)
63. Smoker WR, Harnsberger HR. Differential diagnosis of head and neck lesions based on their space of origin. 2. The infrahyoid portion of the neck. AJR. American journal of roentgenology. 1991 Jul;157(1):155-9. Doi: 10.2214/ajr 157.1.2048511. https://doi.org/10.2214/ajr.157.1.2048511

Student's Journal of Health Research Africa
e-ISSN: 2709-9997, p-ISSN: 3006-1059
Vol.6 No. 9 (2025): September 2025 Issue
https://doi.org/10.51168/sjhrafrica.v6i9.2227
Review Article

PUBLISHER DETAILS:

Student's Journal of Health Research (SJHR)
(ISSN 2709-9997) Online
(ISSN 3006-1059) Print
Category: Non-Governmental & Non-profit Organization
Email: studentsjournal2020@gmail.com
WhatsApp: +256 775 434 261
Location: Scholar's Summit Nakigalala, P. O. Box 701432, Entebbe Uganda, East Africa